




ORIGINAL ARTICLE

Clinical findings of 21 previously unreported probands with *HNRNPU*-related syndrome and comprehensive literature review

Anna Durkin¹  | Shadi Albaba² | Andrew E. Fry³ | Jenny E. Morton⁴ |
Andrew Douglas^{5,12} | Ana Belezza⁶ | Denise Williams⁴ |
Catharina M.L. Volker-Touw⁷ | Sally A. Lynch⁸ | Natalie Canham⁹ |
Virginia Clowes¹⁰ | Volker Straub¹¹ | Katherine Lachlan¹² | Frances Gibbon¹³ |
Mayy El Gamal¹³ | Vinod Varghese³ | Michael J. Parker¹⁴ |
Ruth Newbury-Ecob¹⁵ | Peter D. Turnpenny¹⁶ | Alice Gardham¹⁷  |
Neeti Ghali¹⁷ | Meena Balasubramanian^{14,18} 

¹Medical School, University of Sheffield, Sheffield, UK

²Sheffield Diagnostic Genetics Service, Sheffield Children's NHS Foundation Trust, Sheffield, UK

³Institute of Medical Genetics, University Hospital of Wales, Cardiff, UK

⁴West Midlands Regional Clinical Genetics Service and Birmingham Health Partners, Birmingham Women's and Children's Hospitals NHS Foundation Trust, Birmingham, UK

⁵Human Development and Health, Faculty of Medicine, University of Southampton, Southampton, UK

⁶Guy's and St Thomas Clinical Genetics Service, London, UK

⁷Department of Genetics, Division Laboratories, Pharmacy and Biomedical Genetics, University Medical Centre Utrecht, University of Utrecht, Utrecht, Netherlands

⁸Department of Clinical Genetics, Our Lady's Children's Hospital, Crumlin, Dublin, UK

⁹Clinical Genetics Division, Liverpool Clinical Genetics Service, Liverpool, UK

¹⁰Cambridge Clinical Genetics Service, Addenbrooke's Hospital, Cambridge, UK

¹¹Newcastle Clinical Genetics Service, Newcastle, UK

¹²Wessex Clinical Genetics Service, Princess Anne Hospital, Southampton, UK

¹³Department of Paediatric Neurology, Noah's Ark Children's Hospital for Wales, Heath Park, Cardiff, UK

¹⁴Sheffield Clinical Genetics Service, Sheffield Children's NHS Foundation Trust, Sheffield, UK

¹⁵Bristol Clinical Genetics Service, University Hospitals of Bristol NHS Trust, Bristol, UK

¹⁶Exeter Medical Genetics Service, University of Exeter, Exeter, UK

¹⁷London North West University Healthcare NHS Trust Genetics Service, Middlesex, UK

¹⁸Academic Unit of Child Health, University of Sheffield, South Yorkshire, UK

Correspondence

Meena Balasubramanian, Sheffield Clinical Genetics Service, Sheffield Children's Hospital NHS Foundation Trust, Western Bank, Sheffield S10 2TH.
Email: meena.balasubramanian@nhs.net

Funding information

the Health Innovation Challenge Fund, Grant/Award Number: HICF-1009-003

Abstract

With advances in genetic testing and improved access to such advances, whole exome sequencing is becoming a first-line investigation in clinical work-up of children with developmental delay/intellectual disability (ID). As a result, the need to understand the importance of genetic variants and its effect on the clinical phenotype is increasing. Here, we report on the largest cohort of patients with *HNRNPU* variants. These 21 patients follow on from the previous study published by Yates et al. in 2017 from our group predominantly identified

This is an open access article under the terms of the Creative Commons Attribution License, which permits use, distribution and reproduction in any medium, provided the original work is properly cited.

© 2020 The Authors. *American Journal of Medical Genetics Part A* published by Wiley Periodicals, Inc.

from the Deciphering Developmental Disorders study that reported seven patients with *HNRNPU* variants. All the probands reported here have a *de novo* loss-of-function variant. These probands have craniofacial dysmorphic features, in the majority including widely spaced teeth, microcephaly, high arched eyebrows, and palpebral fissure abnormalities. Many of the patients in the group also have moderate to severe ID and seizures that tend to start in early childhood. This series has allowed us to define a novel neurodevelopmental syndrome, with a likely mechanism of haploinsufficiency, and expand substantially on already published literature on *HNRNPU*-related neurodevelopmental syndrome.

KEYWORDS

DDD study, exome sequencing, *HNRNPU*, intellectual disability, seizures

1 | INTRODUCTION

The clinical application of exome sequencing is becoming more important in the treatment of undiagnosed rare genetic conditions (Need et al., 2012). The cost of exome sequencing has decreased, the processing speed has increased, and there has been an increase in accuracy meaning that exome sequencing is becoming more common as a molecular diagnostic test for those with a rare genetic disorder.

HNRNPU (OMIM *602869) is located on chromosome 1 between bands q43 and q44. Pathogenic variants within this gene have been associated with several different phenotypes including Early Infantile Epileptic Encephalopathy (EIEE), intellectual disability (ID), and craniofacial dysmorphism (OMIM #617391: Epileptic encephalopathy; early infantile, 54). It has been shown that *HNRNPU* is expressed in the adult brain, heart, kidney, and liver with the highest expression in the cerebellum (Thierry et al., 2012). Whole exome sequencing studies suggested haploinsufficiency as the main mechanism of pathogenicity in *HNRNPU*, with loss-of-function variants predominantly reported in association with disease (Leduc et al., 2017).

In this study, we describe the clinical data of 21 probands with previously unreported, predicted pathogenic, *de novo* *HNRNPU* variants. These *HNRNPU* variants were primarily identified through the Deciphering Developmental Disorders (DDD) study and through personal contact with clinicians following publication of the earlier series (Yates et al., 2017). We then collated the information on the clinical phenotype and genotype, which follows on from a previous study looking at seven individuals.

We have seen the reinforcement of previous findings such as a strong link between *HNRNPU* and craniofacial dysmorphism, ID, speech and language impairment, behavioral abnormalities, and seizures. We further found data to support a possible link between *HNRNPU* and cardiac abnormalities.

2 | MATERIALS AND METHODS

2.1 | Editorial policies and ethical considerations

The DDD study has UK Research Ethics Committee approval (10/H0305/83, granted by the Cambridge South REC, and GEN/284/12 granted by the Republic of Ireland REC).

2.2 | Methods

We identified 21 probands to be involved in this study. Although more probands were identified with variants of uncertain clinical significance and/or unknown inheritance, we narrowed down our inclusion criteria to only include *de novo* variants that were classified as likely pathogenic or pathogenic (Class 4 or 5, respectively) using the American College Medical Genetics (ACMG) variant classification system (Richards et al., 2015). Of the 21 probands identified in this study, 16 were identified through the DDD study via a regional genetics center. The proband and their parents all underwent trio whole exome sequencing where the *HNRNPU* variant was identified. One proband was identified through clinical exome, and the remaining four probands were identified by direct contact with other clinicians.

A systematic method was used to perform an initial search for relevant literature. The databases used include Web of Science, MEDLINE via Ovid, PubMed, and The Cochrane Library. Searches were undertaken using combinations of *HNRNPU*, clinical phenotype, seizures, and ID. Publications were used based on their title, then the abstract and further publications were identified through the references of included papers using the snowball method. We only included papers that used more than one proband.

We have presented our findings as percentages of the data available in this cohort.

3 | RESULTS

3.1 | Proband 1

Proband 1 was a female born to non-consanguineous parents with no remarkable family history. The pregnancy was complicated by bleeding in the third trimester. She was born at 41 weeks' gestation. She had feeding difficulties as she was sleepy and floppy. Her birth weight was 3.2 kg (33rd percentile). She had a moderate global developmental delay and absence seizures. She also had generalized neonatal hypotonia. In view of her clinical phenotype, the differential diagnosis

prior to recruitment to DDD included Prader–Willi syndrome and myotonic dystrophy. Her magnetic resonance imaging (MRI) of the brain was normal. The age of last evaluation was 0.67 years.

3.2 | Proband 2

Proband 2 was a male born to non-consanguineous parents with no significant family history. The pregnancy was uncomplicated. He was born at 28 weeks' gestation. He was an in-patient for 5 weeks after birth, with no known feeding problems. His birth weight was 1.984 kg (99th percentile). He sat independently at 6 months old, started speaking at 13 months, and walked independently at 2–2.5 years old. He suffered from seizures and had developmental regression, ID, and behavioral concerns. His craniofacial dysmorphism included microcephaly and sparse, thin eyebrows. His MRI brain imaging was reported to be abnormal, but no further details were available. The age of last evaluation was 11.32 years.

3.3 | Proband 3

Proband 3 was a male born to non-consanguineous parents with no significant family history. The pregnancy was uncomplicated. He was born at 40 weeks' gestation with no complications. He weighed 2.633 kg (third percentile). He had moderate global developmental delay, hearing impairment and hirsutism. He had short stature, broad thumbs, and cryptorchidism. He also suffered from seizures. He sat independently at 10 months, spoke his first words at 18 months, and walked at 20 months. The age of last evaluation was 16.24 years.

3.4 | Proband 4

Proband 4 was a male born to non-consanguineous parents with no significant family history. The pregnancy was uncomplicated. He was born at 40 weeks' gestation; he had feeding difficulties requiring nasogastric tube (NGT) feeding. His birth weight was 2.492 kg (first percentile). He had global developmental delay and generalized tonic-clonic seizures. His craniofacial dysmorphism included a cupped ear, brachycephaly, widely spaced teeth, bilateral ear pits, hooded eyelids, and a frontal upsweep of hair. His delayed development and facial features were reminiscent of Angelman syndrome. He sat independently at 18 months, walked independently and spoke his first words between 2.5–3 years. He had normal MRI brain imaging. The age of last evaluation was 10.95 years.

3.5 | Proband 5

Proband 5 was a female born to non-consanguineous parents with no significant family history. Her mother suffered from hypothyroidism. Her father had widely spaced teeth. The pregnancy was complicated

by an abnormal scan. She was born at 32 weeks' gestation and was admitted to Special Care Baby Unit (SCBU).

Her birth weight was 2.12 kg (92nd percentile). She had global developmental delay. She walked independently at 2.5–3 years and her first words were at 5 years old. She had short stature accompanied with childhood-onset truncal obesity. Her craniofacial dysmorphism included delayed eruption of permanent teeth, widely spaced teeth, a high-arched palate, and cleft lip and palate. She suffered from seizures. She had normal MRI brain imaging. The age of last evaluation was 12.58 years.

3.6 | Proband 6

Proband 6 was a female born to non-consanguineous parents with no significant family history. The pregnancy was uncomplicated, and she was born at 41 weeks' gestation. Her birth weight was 4.02 kg (90th percentile). She had moderate global developmental delay and a possible impairment of speech. She sat independently at 9 months. She walked independently at 2–2.5 years. Her first words were between the ages of 2.5–3 years. At the age of 6, she was able to speak two- to three-word sentences. She had moderate to severe ID. She also suffered from behavioral disorders including sensory issues, self-harm, and aggression toward family members, destructive to toys, and had no sense of danger. She had bilateral postaxial hand polydactyly, right foot polydactyly, and muscular hypotonia. She was also wheelchair-bound due to marked ligamentous laxity and obesity. She suffered from absence seizures with an atonic element, which started at the age of 10 months. Her tonic-clonic seizures are currently under control.

Her MRI brain imaging showed stable symmetrical white matter signal abnormalities throughout the brain; however, this predominantly affected the periventricular regions of both the parietal lobes and frontal lobes. There were also stable simple cysts adjacent to the temporal horn of the right lateral ventricle in the region of the hippocampus (Figure 1). The age of last evaluation was 2.77 years.

3.7 | Proband 7

Proband 7 was a female born to non-consanguineous parents with no significant family history. Ventriculomegaly was detected at the 20-week scan. She was born at 35 weeks' gestation and was admitted to SCBU for 14 days. She was fed through an NGT and discharged on a bottle. Her birth weight was 2.2 kg (33rd percentile). Her craniofacial dysmorphism included nystagmus and strabismus. She also suffered from central hypoventilation, recurrent hand flapping, central hypotonia, and fatigable weakness. In view of her weakness and hypotonia, she was investigated for congenital myasthenic syndrome prior to recruitment to the DDD study. She sat independently and spoke her first words between 2 and 2.5 years. She had normal MRI brain imaging. The age of last evaluation was 2.58 years.

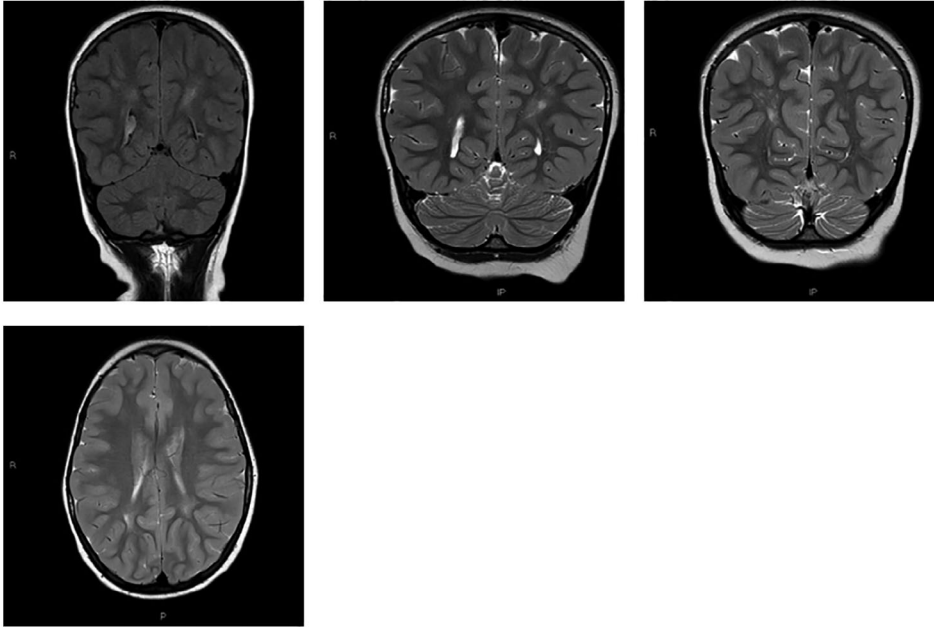
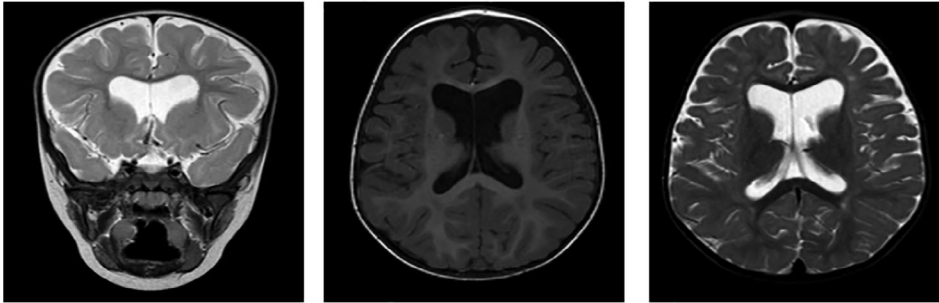
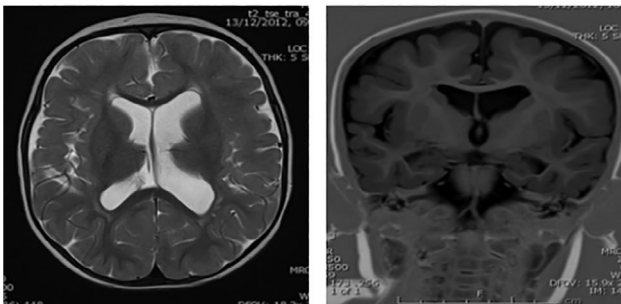
(a) Patient 6: [Coronal T1 and axial T2 weighted image]

FIGURE 1 (a) Patient 6: MRI brain imaging (aged 16 months) showed stable symmetrical white matter signal abnormalities throughout the brain; however, this predominantly affected the periventricular regions of both parietal lobes and frontal lobes. There were also stable simple cysts adjacent to the temporal horn of the right lateral ventricle in the region of the hippocampus (shown in arrow). (b) Patient 8: MRI brain imaging was abnormal with enlargement of the frontal horns of the lateral ventricles and some delayed myelination. (c) Patient 19: MRI brain imaging (aged 13 months) showed periventricular leukomalacia with no other abnormalities. MRI, magnetic resonance imaging

(b) Patient 8: [Coronal T1, axial T1 and axial T2 weighted image]**(c) Patient 19: [Axial T2 & Coronal T1 weighted image]****3.8 | Proband 8**

Proband 8 was a female born to non-consanguineous parents with no significant family history. The pregnancy was complicated by intrauterine growth retardation. She was born at 39 weeks' gestation. Her birth weight was 2.66 kg (10th percentile). She had global

developmental delay. She first socially smiled at 6 weeks and sat independently at 12 months. Her craniofacial dysmorphism consisted of a prominent median palatal raphe. She was born with congenital cardiac abnormalities, namely atrial septal defect (ASD) and a patent ductus arteriosus (PDA). She suffered from seizures. Her MRI brain imaging was abnormal with enlargement of the frontal horns of the lateral

ventricles and some delayed myelination (Figure 1). The age of last evaluation was 4.09 years.

3.9 | Proband 9

Proband 9 was a female born to non-consanguineous parents. There were no complications in the pregnancy, and she was born at 41 weeks' gestation. She was admitted to SCBU for 1 day but had no feeding problems. Her birth weight was 2.68 kg (fifth percentile). She had a global development delay including delayed speech and language. She sat independently at 6 months, walked independently at 2–2.5 years, and her first words were at 3–4 years. Her craniofacial dysmorphism consisted of brachycephaly, long eyelashes, long philtrum, low anterior hairline, microcephaly, and up-slanted palpebral fissures. She suffered from generalized tonic-clonic seizures. Due to her facial features, she was considered to clinically have Cornelia de Lange syndrome prior to recruitment to DDD study. Her MRI brain imaging was normal. The age of last evaluation was 15.85 years.

3.10 | Proband 10

Proband 10 was a female born to non-consanguineous parents with two affected siblings, raising the possibility of gonadal mosaicism in one of the parents. Her mother had a bleed in her third trimester of pregnancy. The proband was born at 39 weeks' gestation with no complications. Her birth weight was 2.655 kg (10th percentile) and her head circumference was 34 cm (51st percentile). She had developmental regression and profound ID. Her first social smile was at 9 weeks and she sat independently at 12 months. She could speak single words at 2 years old; however, she regressed to no speech. At the age of 3–4 years, she was able to "cruise" around furniture. However, she had regressed and now lost this skill. Her craniofacial dysmorphism included progressive microcephaly, synophrys, widely spaced teeth, and bruxism. She had functional respiratory abnormality. She suffered from focal seizures with generalization as well as episodes of nonconvulsive status. She had episodes of clustering focal seizures resistant to standard antiepileptic medications. Her MRI brain imaging was abnormal with simplified gyral patterns, reduced white matter volume, and a slender corpus callosum. The age of last evaluation was 11.75 years.

3.11 | Proband 11

Proband 11 was a female born to non-consanguineous parents with no significant family history. Assisted reproduction (intracytoplasmic sperm injection) was used in conception. The pregnancy was complicated by decreased fetal movements toward the end of pregnancy. She was born at 40 weeks' gestation but spent 7 days in SCBU requiring NGT feeding because of feeding difficulties. Her birth weight was 3.54 kg (62nd percentile). At the age of 15 years, her head

circumference was 53.4 cm (ninth percentile). She exhibited some stereotypical hand movements and bruxism. She was not notably dysmorphic but had slender hands and feet, a high palate, and misaligned upper incisors.

She had severe global developmental delay, crawling at 16 months and walking independently at 2.5 years. Her first words were at 12 months but despite initially learning several words and starting to put two words together, these were subsequently lost after the age of 2 years along with the ability to sign. However, this was followed by slow and gradual progress and aged 15 years, she now has a vocabulary of around 15 words, but their pronunciation is indistinct. She can use a tablet computer to find and view photographs and communicate using this device. She can mobilize short distances but has a wide and stiff gait. She was toilet-trained by day and was generally dry at night. Her behavior can be affectionate but also stubborn at times. Her differential diagnosis prior to recruitment to DDD study included Angelman syndrome, Rett syndrome, and Smith Magenis syndrome in view of her facial dysmorphism, seizure history, and developmental regression.

At 9 months, she had a febrile convulsion. Another seizure occurred aged 2 years, and thereafter, she developed more frequent seizures including absences and tonic-clonic fits. After a trial of carbamazepine and sodium valproate with little effect, her seizures were controlled with topiramate and levetiracetam. As a teenager, she is currently only on levetiracetam. Her MRI brain imaging was normal. The age of last evaluation was 9.99 years.

3.12 | Proband 12

Proband 12 was a male born to non-consanguineous parents with no significant family history. There were no complications in pregnancy, and he was born at 40 weeks' gestation with a birth weight of 3.18 kg (22nd percentile). He had a cognitive impairment and autism. He had speech therapy at school and went to a special needs school. His craniofacial dysmorphism included prominent, heavy, wide arched eyebrows, a triangular shaped face, and flat cheekbones. He suffered from two seizures in his lifetime. His phenotype was reminiscent of Cornelia de Lange syndrome particularly his wide arched eyebrows and facial dysmorphism prior to recruitment to DDD study. The age of last evaluation was 16.68 years.

3.13 | Proband 13

Proband 13 was a female born to non-consanguineous parents with no significant family history. There were no complications of pregnancy. She was born at 37 weeks' gestation and admitted to the SCBU for 2 days. Her birth weight was 2.855 kg (56th percentile). She had a severe global developmental delay and stereotypy. She sat independently at 15 months and walked independently at 2.5–3 years. Her craniofacial dysmorphism included strabismus, drooling, prominent nasal bridge, and a wide nasal bridge. She had a short fourth and

fifth metacarpal and tapered finger. Her gait was broad-based. She suffered from seizures. Her seizures (tonic/tonic-clonic) started at the age of 12 months. These improved with sodium valproate and lamotrigine, but she continued to have frequent drop attacks. Episodic hyperventilation started in the first 2 years of life and a computerized tomography (CT) of brain at 2.5 years of age showed minor frontal atrophy. She has never had any further imaging of the brain. One of the most striking clinical features was her episodic hyperventilation followed by quite prolonged apnoeas where she became cyanotic. She also had hand-wringing and bruxism. In view of the hand-wringing, hyperventilation, seizures, and strabismus, her differential diagnosis prior to recruitment to DDD study was Rett syndrome and Pitt-Hopkins syndrome. The age of last evaluation was 17.63 years.

3.14 | Proband 14

Proband 14 was a male born to non-consanguineous parents with no significant family history. He was born at 40 weeks' gestation following an uncomplicated pregnancy. He was a breech delivery and required 1 day at the SCBU but did not have any feeding problems. His birth weight was 2.86 kg (ninth percentile). He had a slender build, with a weight and height at -2 SD. He had a global developmental delay with a total intelligence quotient of 52. He also had delayed speech and language skills. He walked independently and spoke his first words at 2 years old. His craniofacial dysmorphism included dolichocephaly, prominent forehead, down-slanting palpebral fissures, slightly low hanging columella, and a thin upper lip as well as long fingers and toes. His initial febrile seizures started at the age of 7 years, which progressed to focal seizures that were well controlled with sodium valproate. His MRI brain imaging was normal. The age of last evaluation was 13 years.

3.15 | Proband 15

Proband 15 was a male born to non-consanguineous parents with no significant family history. At 5 months' gestation, his mother fell onto her abdomen. At the antenatal screening, there was a 1 in 24 risk of Down syndrome, but the amniocentesis was normal. There was an abnormal 20-week scan showing mild tricuspid regurgitation. He was born at 39 weeks in a good condition with a birth weight of 3.2 kg (91st percentile).

Developmentally, he sat independently for the first time aged 12 months, walked independently aged 2 years, and his first words were at the age of 2.5 years. He spoke in single words at the age of 5 and did not understand simple instructions. He had a global developmental delay with moderate motor delay and severe speech and language delay. He had a moderate ID, meaning he was in a special unit in a mainstream school and received one-to-one help. He had some aggressive outbursts and had no sense of danger. His craniofacial dysmorphism included left-sided plagiocephaly, torticollis, low-set ears, prominent forehead, epicanthic folds, prominent nasal tip, and

sparse hair. He also suffered from trivial tricuspid regurgitation. His gait was unsteady, and he had frequent falls.

He suffered from seizures that began at the age of 13 months. He had his last seizure at 4 years old and he is currently not on any anticonvulsant medication. He initially presented with typical febrile convulsions, later some became afebrile episodes and vacant spells. He suffered from intermittent left extropia and mild hypermetropia. He also had low muscle tone, particularly core tone. His phenotype was reminiscent of Angelman syndrome. His MRI brain imaging was normal. The age of last evaluation was 5.7 years.

3.16 | Proband 16

Proband 16 was a 20-year-old female referred to the 100,000 genomes project with severe ID and epilepsy. She was born post-term with fetal distress at delivery. She weighed 3.7 kg (75th–91st centile) at birth.

She had always been obese with hyperphagia. At 20 years of age, she had severe ID with absent speech and nonmobile. Her craniofacial dysmorphism included dysplastic earlobes, short palpebral fissures, broad nasal bridge, hypoplastic alae nasi, tented upper lip, and a prominent jaw. She had small hands and feet with tapering fingers, bilateral single palmar creases, and short fifth fingers. She suffered from postnatal microcephaly and her first seizure was at 6 months. She suffered with epileptic encephalopathy since the age of 2, when spasticity became evident subsequently. Her epilepsy was controlled with sodium valproate. She has Rett-like features including bruxism. Her MRI brain imaging was normal. There were three healthy siblings born subsequently. The age of last evaluation is 20 years of age.

3.17 | Proband 17

Proband 17 was a 12-year-old girl, the second child born to non-consanguineous parents who experienced two early spontaneous miscarriages. They had a healthy son 18 months older than the proband. The mother was taking fluoxetine at the time of this unplanned conception, but the pregnancy was otherwise uncomplicated. She had a normal delivery at 39 weeks' gestation with a birth weight of 3.175 kg (50th centile). She initially had a low temperature and did not feed well. There were concerns about poor eye contact at 5 weeks and she suffered a varicella infection at 8 weeks. She demonstrated growth delay and global developmental delay. At 3 years, she could stand with support and crawl, had babble but no speech, and could not feed herself. She manifested hand-wringing movements, prompting testing for Rett syndrome which was negative. She sat and walked independently at 3 years and 5–8 years, respectively. Currently, she has severe ID with no speech, her only word being "hi-ya" and she was not toilet trained. She was generally content, capable of tantrums, could use a tablet computer, and followed some instructions slowly. She slept poorly.

Aged 14 months, she developed a seizure disorder that was subsequently well controlled on sodium valproate and lamotrigine. Her last generalized tonic-clonic seizure occurred at 2 years though absences continue infrequently. Her craniofacial dysmorphism consisted of mild synophrys and a short nose, and she has short finger and toes with fifth finger clinodactyly. She wears glasses for alternating divergent strabismus. Her MRI brain imaging was normal. The age of last evaluation was 12 years of age.

3.18 | Proband 18

Proband 18 was a male born to non-consanguineous parents with no significant family history. He was born at 36 weeks' gestation and had difficulties in establishing breast feeding. His birth weight was 2.155 kg (eighth centile). He had a severe developmental delay and a regression of language; he was only able to say "mummy" but was able to say two to three sentences previously. He smiled socially for the first time aged 8 weeks, sat independently aged 14 months, and walked independently at the age of 2–2.5 years.

His craniofacial dysmorphism included coarse facial features, epicanthus, high arched eyebrow, long palpebral fissure, trigonocephaly, widely spaced teeth, and a wide mouth. He also had prominent fingertip pads and a broad thumb. He also suffered from tonic-clonic seizures, atypical absences, recurrent absence status, probable atonic seizures with later emergence of tonic seizures, and gelastic seizures. Despite being on lacosamide, sodium valproate, and phenytoin, he was still having several seizures a day. He was reported to have a fluctuating pattern of functional ability. When he had prolonged periods of seizures and nonconvulsive status, his functional mobility, awareness and communication, general well-being including appetite and sleep, could be severely disrupted. He had a pattern of being chronically fatigued and very slow to get up in the morning. He also had difficulties with motor initiation.

He was commenced on a nicotine patch trial to reduce the number of seizures. Due to the severity of his seizures, he had been put into an induced coma and been intubated for a long period. He had an abnormal MRI that noted unusual areas of altered signal intensity within the corpus callosum; however, this had resolved 3 years later on repeat imaging. The age of last evaluation was 13.9 years.

3.19 | Proband 19

Proband 19 was a female proband born to non-consanguineous parents with no significant family history. During pregnancy, the mother suffered with maternal pre-eclampsia; however, there was normal maternal serology and normal antenatal scans. The proband was born at 28 + 5 weeks' gestation by emergency cesarean section. She was born in good condition with an appearance, pulse, grimace, activity, and respiration (APGAR) score of 9 at both 1 and 5 min of age. She was admitted to the SCBU for 45 days where she was treated conservatively for presumed necrotizing enterocolitis. Her birth weight was

0.865 kg (ninth centile) and her head circumference at birth was 23.7 cm (second centile).

She had generally delayed development; she did not walk until the age of 2 years and did not speak until 3.5 years. She has never spoken in sentences. She was also noted to have autistic traits in the form of frequent hand wringing and delay in social communication, which initially raised the suspicion for Rett syndrome before further studies were undertaken. She had problems with bilateral adhesive otitis media, which required grommet insertion. She also had early onset exotropia that entailed wearing glasses early in her life. She has never been successfully toilet-trained and has always suffered with constipation. Her craniofacial dysmorphism included broad forehead and small chin with a degree of lumbar lordosis. Hand stereotypies were also observed.

Her seizures started at 10 months of age that were initially febrile seizures, followed by prolonged afebrile episodes. After a period of reasonable control of seizures on sodium valproate, she started having seizures again at the age of 5 years and continued to have different types of seizures: absence, myoclonic, and episodes of nonconvulsive status epilepticus that required prolonged hospital admissions and was confirmed by electroencephalogram. They were resistant to multiple antiepileptic medications. Temporary improvement with ketogenic diet had been observed, but this was not tolerated for more than a few months on each occasion because of gastrointestinal side effects. Her MRI brain imaging (aged 13 months) showed periventricular leukomalacia with no other abnormalities (Figure 1c). The age of last evaluation was 8.5 years.

3.20 | Proband 20

Proband 20 was a female born to non-consanguineous parents with no remarkable family history. There were abnormal scans during pregnancy where the proband appeared small for their dates. She was born at 40 + 9 weeks' gestation and was admitted to SCBU due to transient tachypnoea of the new-born for a brief period. Her birth weight was 2.68 kg (second–ninth centile). She has moderate to severe developmental delay. She does speak but is very delayed with sentences only developing over the past 5 years. She has no formal behavioral disorder diagnosed but can be difficult, for example, screaming when unhappy.

Craniofacial dysmorphism included up-slanted palpebral fissures, long eyelashes, and a thin upper lip. Other aspects of her phenotype to note are her broad thumbs, scoliosis, ASD that closed early in life, pes planus, cold feet, and digestive problems that include bringing up a lot of phlegm. When she was younger, the proband's phenotype was clinically thought to be Cornelia de Lange syndrome.

She suffered from seizures at 16 months but is currently seizure free on medication. She had an encephalopathic illness at around 16 months. She sat independently at 2 years and spoke one word at this time. Her MRI brain imaging was normal. The age of last evaluation was 23 years.

3.21 | Proband 21

Proband 21 was a male born to non-consanguineous parents. Prior to this pregnancy, there were three miscarriages. There were no complications of pregnancy. He was born at 40 + 2 weeks and weighed 2.46 kg (second centile). He had global developmental delay, which included many single words aged 5. He was formally diagnosed with autism spectrum disorder at the age of five. His craniofacial dysmorphism included frontal bossing, prominent metopic suture, hypertelorism, long eyelashes, long smooth philtrum, sparse eyebrows medially, down-turned corners of the mouth, flattened

nasal bridge, and a short nose. Other aspects of the phenotype to note are bilateral postaxial polydactyly, orchidopexy for undescended testes, hypotonia, joint laxity, and hypothyroidism, which is currently well treated with thyroxine. Relevant family history included the mother suffering from hypothyroidism that is also treated with thyroxine.

This proband also suffered from seizures from the age of 16 months with initial febrile seizures and is currently treated with levetiracetam. There is no epileptic encephalopathy present. He sat independently at 16 months, walked independently at 3 years, and he spoke three words at 14 months. He is the only affected member of

TABLE 1 Sequencing results

Patient	HNRNPU variant	Predicted protein change	ACMG criteria	Classification
1	c.619C>T	p.(Gln207*)	PVS1, PM2-M, PS2-S	Pathogenic
2	c.1925_1926del	p.(Leu642Profs*5)	PVS1, PM2-M, PS2-S	Pathogenic
3	c.1450C>T	p.(Arg484*)	PVS1, PM2-M, PS2-S	Pathogenic
4	c.395_401del	p.(Asn132Thrfs*63)	PVS1, PM2-M, PS2-S	Pathogenic
5	c.2083_2084del	p.(Ser695Trpfs*6)	PVS1, PM2-M, PS2-S	Pathogenic
6	c.1836del	p.(Tyr613Ilefs*11)	PVS1, PM2-M, PS2-S	Pathogenic
7	c.67C>T	p.(Arg23*)	PVS1, PM2-M, PS2-S	Pathogenic
8	c.692-1G>A	p.? (splice site variant)	PVS1, PM2-M, PS2-S, PP3-P	Pathogenic
9	c.706_707del	p.(Glu236Thrfs*6)	PVS1, PS2-S, BS2-S	Pathogenic
10	c.1088G>A	p.(Trp363*)	PVS1, PM2-M, PS2-S	Pathogenic
11	c.1743+1G> C	p.? (splice site variant)	PVS1, PM2-M, PS2-S, PP3-P	Pathogenic
12	c.1801C>T	p.(Arg601*)	PVS1, PM2-M, PS2-S	Pathogenic
13	c.847_857del	p.(Phe283Serfs*5)	PVS1, PS2-S, BS2-S	Pathogenic
14	c.837_839del	p.(Glu279del)	PS2-S, PM2-M, PM4-M	Likely pathogenic
15	c.2167+35_*4156del	p.? (deletion of last three exons)	PVS1-S, PS2-S, PM2-M	Pathogenic
16	c.1089G>A	p.(Trp363*)	PVS1, PM2-M, PS2-S	Pathogenic
17	c.1641del	p.(Asp548Ilefs*5)	PVS1, PM2-M, PS2-S	Pathogenic
18	c.1681del	p.(Gln561Serfs*45)	PVS1, PM2-M, PS2-S	Pathogenic
19	c.454_466del	p.(Ala152Thrfs*41)	PVS1, PM2-M, PS2-S	Pathogenic
20	c.706_707del	p.(Glu236Thrfs*6)	PVS1, PM2-M, PS2-S	Pathogenic
21	c.712_715del	p.(Lys238AlafsTer100)	PVS1, PM2-M, PS2-S	Pathogenic

PVS1 Null variant (nonsense, frameshift, canonical ± 1 or 2 splice sites, initiation codon, single, or multiexon deletion) in a gene where LOF is a known mechanism of disease

PS2 *de novo* (both maternity and paternity confirmed) in a patient with the disease and no family history

PM2 Absent from controls (or at extremely low frequency if recessive) in the Genome Aggregation Database (gnomAD)

PM4 Protein length changes as a result of in-frame deletions/insertions in a nonrepeat region or stop-loss variants

PP3 Multiple lines of computational evidence support a deleterious effect on the gene or gene product (conservation, evolutionary, splicing impact, and so on)

BS2 Observed in a healthy adult individual for a dominant with full penetrance expected at an early age

-S Strong level evidence

-M Moderate level evidence

-P Supporting level evidence

Note: HNRNPU variant identified in this study alongside the predicted protein change, ACMG variant classification criteria and final classification. Variant nomenclature using gene transcript NM_031844.2 (GRCh37). Population data were checked using gnomAD v2.1.1 (controls) data set, which can be accessed through <https://gnomad.broadinstitute.org>. PVS1 weight was determined using guidelines in Abou Tayoun et al., 2018. PS2 weight used at a strong level since *de novo* status was confirmed in all cases.

the family. His MRI brain imaging was reported normal. The age of last evaluation was 5 years.

3.22 | Sequencing results

Table 1 provides a list of pathogenic/likely pathogenic variants in the 21 probands reported here. The table also provides ACMG criteria for classification of variant pathogenicity. Variant nomenclature is according to gene transcript NM_031844.2 (GRCh37). Figure 2 shows details of all the variants so far reported in *HNRNPU* including variants identified in this study. Tables 4 and 5 provide a list of all the variants so far published in *HNRNPU* to compare with Table 1.

4 | DISCUSSION

4.1 | Gene function

The *HNRNPU* gene encodes for HNRNPU (Heterogeneous nuclear ribonucleoprotein U) and has been linked to several different functions including X-inactivation, genomic stability, telomere-length regulation and nuclear chromatin, and transcription organization.

The role of HNRNPU in X-inactivation involves a long piece of noncoding RNA called Xist, which is central to this process. It has been found that HNRNPU protein is required for Xist RNA association with the X chromosome and thereafter inactivation. Embryonic stem cell research has shown that cells that do not express HNRNPU were unable to form an inactive X chromosome, resulting in biallelic expression of X-linked genes (Hasegawa et al., 2010). HNRNPU is the

protein that allows the Xist RNA to coat the inactive X chromosome (Xi) through its DNA as well as its RNA binding (Hasegawa et al., 2010). HNRNPU is made up of three conserved domains: scaffold attachment factor (SAF), SPRY, and RGG. The SAF domain oversees the scaffold matrix, the SPRY domain is a Spla and ryanodine receptor with no known function, and RGG is an RNA-binding domain made up of RGG repeats. The RGG site is important as it mediates attachment to the Xist RNA while HNRNPU interacts directly with the Xist via the RNA-binding domain.

HNRNPU has been found to code for a family of proteins that are able to bind nucleic acids and heterogeneous nuclear RNA (HnRNA). HnRNA can bind to DNA and RNA, and it binds a scaffold attachment region (SAR) to the DNA, indicating where the nuclear matrix should attach. Therefore, this suggests that it plays a role in regulating interphase via caRNA, which is a chromatin-associated RNA, and resulting in the stability of the genome (Nozawa et al., 2017).

There is also evidence to suggest that HNRNPU is also important as an RNA polymerase (Pol II) elongation inhibitor, consequently preventing RNA Pol II-mediated transcription (Bi et al., 2013).

4.2 | HNRNPU-related syndrome

From the data that we have collected, there are some common patterns in the phenotypic expression of the individuals. These include 95% of the probands that have craniofacial dysmorphism, the most common including palpebral fissure abnormalities (24%), microcephaly (19%), and wide spaced teeth (19%). Of the 21 probands, 20 of these have seizures recorded. Of these seizures, 25% have absence seizures and 25% have generalized tonic-clonic seizures.

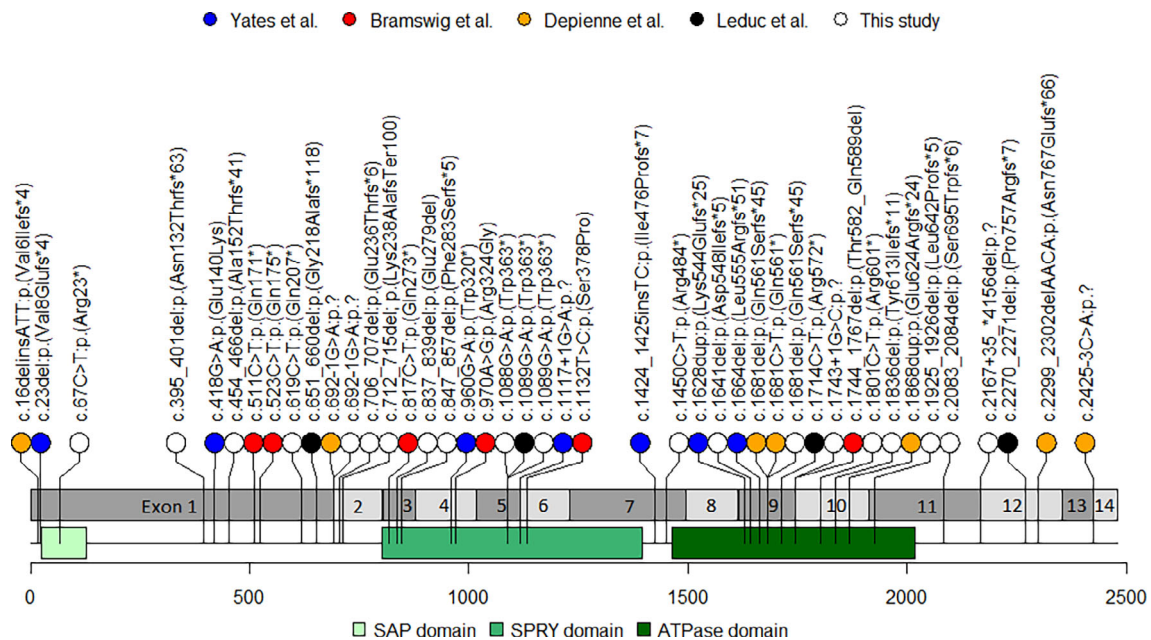


FIGURE 2 Variant interpretation plot for all probands with pathogenic *HNRNPU* variants in this cohort and published literature [Color figure can be viewed at wileyonlinelibrary.com]

TABLE 2 The more common phenotypes

	Total (%)
Developmental delay	95
Developmental regression	10
Moderate	15
Moderate to severe	5
Severe	30
Present	35
Data not available	5
Degree of intellectual disability	52
ID present but severity not known	55
Moderate	18
Moderate to severe	9
Severe	18
Data not available	48
Craniofacial dysmorphism	95
Microcephaly	20
Abnormal head shape	25
Prominent forehead	15
High arched, thin eyebrows	15
Palpebral fissure abnormalities	25
Epicanthus	10
Abnormalities of ear	25
Abnormalities of hair	15
Synophrys	10
Wide spaced teeth	20
Delayed eruption/maligned upper incisors	10
Bruxism	15
High palate	10
Hypermetropia	10
Data not available	5
Seizures	95
Absence	25
Generalized tonic-clonic	25
Focal	10
Unknown	35
Data not available	5

Another key feature is developmental delay—95% of the probands are recorded as having developmental delay. Of these, 66% also have delayed speech and language skills. In addition to this, 50% also have a degree of ID and 50% have a behavioral disorder from the data recorded. On closer analyses of the phenotypes, they were found to be similar to Cornelia de Lange, Angelman, Rett and Pitt Hopkins syndromes, all of which have specific craniofacial dysmorphism, ID, and behavioral phenotype present showing that this could be part of the *HNRNPU*-related phenotype differential diagnoses. However, most of the craniofacial dysmorphism that were recorded were unique to the proband. Less commonly observed phenotypes included postaxial

polydactyly, PDA, and an atrial septal defect (two probands). Three patients presented with respiratory concerns: breath holding, functional respiratory abnormality, and central hypoventilation.

The main differential diagnosis for *HNRNPU*-related syndrome from our cohort was Rett syndrome with 19% probands noted as having Rett-like phenotypic expressions. The most common reasons for suspecting Rett syndrome were hand wringing, bruxism, delay in social interaction, and hyperventilation. This was followed by Angelman syndrome with 14% probands found to have phenotype similar to this. Angelman syndrome was considered as a differential diagnosis' due to developmental delay, facial features, and an affectionate character. Three probands also had phenotypes similar to Cornelia de Lange with Prader-Willi, myotonic dystrophy, congenital myasthenic syndrome, Fragile X, Smith Magenis syndrome, and Pitt-Hopkins phenotypes, all described as differential diagnoses for patients with *HNRNPU*-related syndrome.

Table 2 describes the phenotype of the cohort reported here with clustering of clinical features wherever applicable. Tables 6 and 7 have all the detailed phenotypic info: Table 6 for probands 1–11 and Table 7 for probands 12–21. The data that we have unearthed adds to the growing body of data on *HNRNPU* showing a particularly strong link between *HNRNPU* and seizures and craniofacial dysmorphisms that we have described in greater detail than previous studies as well as finding possible link to cardiac abnormalities.

4.3 | Literature review

A comprehensive review of the literature published so far on *HNRNPU*-related neurodevelopmental syndrome shows data from a further six papers that have reported on clinical features (Table 3) with individuals shown to have variants in *HNRNPU* (see Supporting Information). Four of the *HNRNPU* cohorts reported showed that all probands that were included had craniofacial dysmorphism while one did not report data on this, and the remaining paper showed 86% probands having craniofacial dysmorphism. In our cohort, the most commonly observed dysmorphism included widely spaced teeth (19%), microcephaly (19%), and palpebral fissure abnormalities (24%).

All of the previously published studies showed ID in all probands. This is different to our findings, however we included all patients from our cohort and not just those that were assessed due to the data that we have available. Interestingly, however, 95% of our probands had developmental delay. Out of the total 59 probands from all the papers combined, 46 (78%) had a speech and language impairment. This varied between non-verbal to short sentences. The behavioral abnormalities reported tended to show autistic tendencies, aggressive tendencies, or being very happy and social. Of the total number of probands reported of having a behavioral abnormality, 43% had autism or autistic tendencies, 21% had aggressive behavior, and 11% were very social and happy. The less common behavioral phenotypes included obsessive-compulsive disorder and self-stimulatory behavior.

Of the 61 probands with data on seizures, 56 (92%) of these had seizures. In our study, the most common form of seizure was

TABLE 3 Clinical features of patients with HNRNPU variants

	This study	Yates et al. (2017)	Bramswig et al., 2017	Depienne et al., 2017	Thierry et al., 2012	Caliebe et al. (2010)	Leduc et al., 2017
Craniofacial dysmorphism (%)	95	86	100	n/a	100	100	100
Intellectual disability (%)	52	100	100	100	100	n/r	100
Speech and language impairment (%)	67	86	100	100	50	100	100
Behavioral abnormality (%)	52	71	57	n/r	44	50	50
Seizures (%)	95	71	86	86	100	100	100
MR brain abnormality (%)	48	29	71	60	73	100	75
Cardiac abnormality (%)	14	14	67	n/r	n/r	50	n/r
Renal abnormality (%)	0	0	75	n/r	100	25	n/r

Note: n/r indicates not recorded.

TABLE 4 Variants published in the *HNRNPU* by cDNA order, nomenclature using gene transcript NM_031844.2 (GRCh37)

cDNA number	Protein number	Published paper
c.16delinsATT	p.(Val6Ilefs*4)	Depienne et al. (2017)
c.23del	p.(Val8Glufs*4)	Yates et al. (2017)
c.418G>A	p.(Glu140Lys)	Yates et al. (2017)
c.511C>T	p.(Gln171*)	Bramswig et al. (2017)
c.523C>T	p.(Gln175*)	Bramswig et al. (2017)
c.651_660del	p.(Gly218Alafs*118)	Leduc et al. (2017)
c.692-1G>A	p.?	Depienne et al., 2017
c.817C>T	p.(Gln273*)	Bramswig et al. (2017)
c.960G>A	p.(Trp320*)	Yates et al. (2017)
c.970A>G	p.(Arg324Gly)	Bramswig et al. (2017)
c.1089G>A	p.(Trp363*)	Leduc et al. (2017)
c.1117+1G>A	p.?	Yates et al. (2017)
c.1132T>C	p.(Ser378Pro)	Bramswig et al. (2017)
c.1424_1425insTC	p.(Ile476Profs*7)	Yates et al. (2017)
c.1628dup	p.(Lys544Glufs*25)	Yates et al. (2017)
c.1664del	p.(Leu555Argfs*51)	Yates et al. (2017)
c.1681C>T	p.(Gln561*)	Depienne et al., 2017
c.1681del	p.(Gln561Serfs*45)	Depienne et al., 2017
c.1714C>T	p.(Arg572*)	Leduc et al. (2017)
c.1744_1767del	p.(Thr582_Gln589del)	Bramswig et al. (2017)
c.1868dup	p.(Glu624Argfs*24)	Depienne et al., 2017
c.2270_2271del	p.(Pro757Argfs*7)	Leduc et al. (2017)
c.2299_2302delAACA	p.(Asn767Glufs*66)	Depienne et al., 2017
c.2425-3C>A	p.?	Depienne et al., 2017

generalized tonic-clonic seizures 24% and absence seizures 24%. Depienne et al., 2017 showed that 57% had generalized tonic-clonic and 57% had absence seizures, of these 43% of these probands had generalized tonic-clonic and absence seizures.

Thirty-five probands were reported as having a brain abnormality on imaging. The most common abnormalities seen were a thin corpus callosum 14%, wide ventricles 5/35 14%, delayed myelination 14%,

TABLE 5 Copy number variants published in *HNRNPU*

Gene aberration	Published paper
Whole gene deletion (1 patient)	Thierry et al. (2012)
Whole gene deletion (1 patient)	Caliebe et al. (2010)
Intragenic duplication of exons 1–3 (1 patient)	Bramswig et al. (2017)

Note: Please note that whole gene deletions were part of a larger deleted region included other adjacent genes.

generalized atrophy 9%, and cerebellar vermis atrophy 6%. From the MRI imaging in our cohort and review of previously published literature, there does not appear to be uniform findings on brain imaging that would help point toward this diagnosis and a normal MRI brain scan would not preclude this as a diagnosis.

Ten probands were recorded as having a cardiac abnormality, these included ASD 50%, PDA 13% transposition of the great vessels 13%, tricuspid atresia 13%, VSD 25%, and pentalogy of Fallot 13% and aortic dilation 13%. Five probands have recorded data on renal abnormalities, these include agenesis of the kidney 60%, unilateral multicystic kidney 20%, and renal pelvic ectasia 20%.

In our cohort, 24% patients were born prematurely (less than 37 weeks). However, when compared with the literature on HNRNPU-related disorder, Leduc et al. (2017) and Bramswig et al. (2017) found that 25% and 14% in their series, respectively, were premature, while Caliebe et al. (2010) and Yates et al. (2017) had no premature births in their cohort. The remaining papers did not record this information. Therefore, it does not appear that prematurity is a consistent feature with HNRNPU-related disorder.

As is demonstrated in the variant plot (Figure 2), all the pathogenic variants reported in *HNRNPU* appear to be loss-of-function variants and almost all of them were de novo. There were very few missense variants reported in the literature so far and this gene has an overall borderline constraint to missense changes (constraint score of $z = 3.37$; $z \geq 3$ predicts gene intolerance to missense variants) (Havrilla, Layer, & Quinlan, 2019). The region with the lowest ratio of observed to expected missense variants using the gnomAD data is mapped to amino acids p.521 to p.640. However, with the limited numbers of identified missense/in-frame deletion/insertion variants in

TABLE 6 Phenotypic data patients 1–11

Patient number	1	2	3	4	5	6	7	8	9	10	11
ID	DDD-290747	DDD-264725	DDD-305034	DDD-266412	DDD-279866	DDD-307385	DDD-305434	DDD-268181	DDD-279875	DDD-259668	DDD-266124
Genotype	c.619C>T	c.1925_1926del	C.1450C>T	c.395_401del	c.2083_2084del	c.1836del	c.67C>T	c.692-1G>A	c.706_707del	c.1088G>A	c.1743+1G>C
Protein change	p.Gln207Ter	p. Leu642ProfsTer5	p.Arg484Ter	p. Asn32ThrfsTer63	p. Ser695TrpfsTer6	p. Tyr613IlefsTer11	p.Arg23Ter	splice_acceptor_variant	p. Glu236ThrfsTer6	p.Trp363Ter	splice_donor_variant
Heterozygous	Het	Het	Het	Het	Het	Het	Het	Het	Het	Het	Het
Gender	F	M	M	M	F	F	F	F	F	F	F
Developmental delay	Moderate, global	Regression	Moderate, global	Global	Global	Moderate, global	n/a	Global developmental delay	Global	Regression, stereotypy	Severe, abnormality of movement
Speech impairment	n/a	n/a	n/a	n/a	n/a	Possibly	n/a	n/a	Delayed	Absent speech	Lost ability to speak but now has 15 words
Degree of ID	n/a	ID present, degree unknown	n/a	n/a	n/a	Moderate to severe	n/a	n/a	n/a	Profound	Severe
Behavior	n/a	Abnormal	n/a	n/a	n/a	Sensory issues, self-harm, aggressive toward family members, destructive to toys, no sense of danger	n/a	n/a	n/a	n/a	Can be affectionate but stubborn
Stature	n/a	n/a	Short	n/a	Short	n/a	n/a	n/a	n/a	n/a	n/a
Craniofacial dysmorphism	n/a	Microcephaly, sparse, and thin eyebrows	Hearing impairment, hirsutism	Cupped ear, brachycephaly, wide spaced teeth, frontal upsweep of hair	Delayed eruption of permanent teeth, high palate, median cleft lip and palate, widely spaced teeth	Hypermetropia	Nystagmus, strabismus	Prominent median palatal raphe	Brachycephaly, long eyelashes, long philtrum, low anterior hairline, microcephaly, up slanted palpebral fissures	Progressive microcephaly, microcephaly, synophrys, widely spaced teeth, bruxism	Narrow palpebral fissures, mild posterior rotation of ears, high palate, maligned upper incisors
Chest/upper limbs/hands:	n/a	Short palm	Broad thumb	Bilateral single transverse palmar creases	n/a	Bilateral postaxial hand polydactyly	n/a	n/a	Clinodactyly of the fifth finger	n/a	Slender hands and feet
Cardiac/other organ abnormality:	Anteriorly placed anus	n/a	Cryptorchidism	n/a	Childhood-onset truncal obesity	Obesity	Hypothyroidism, central hypoventilation, recurrent hand flapping	ASD, PDA	n/a	Functional respiratory abnormality	Feeding difficulties at 15 years, breath-holding/apnoeic episodes
Lower limbs	Absent patellar reflexes	Short foot	n/a	n/a	Short foot	Right foot Polydactyly	n/a	n/a	n/a	Regressed movement	Ataxic broad-based gait
Seizures	+Absence	+	+	+ Generalized tonic-clonic	+	+ Absence seizures with atonic element Tonic-clonic seizures now controlled.	n/a	+	+ Generalized tonic-clonic seizures	+ Focal seizures that become generalized. Can become clustered.	+ Febrile, absence and tonic-clonic fits
Musculature	Generalized neonatal hypotonia	n/a	n/a	n/a	n/a	Muscular hypotonia, wheelchair due to marked ligamentous laxity	Central hypotonia, fatigable weakness	n/a	n/a	n/a	n/a

TABLE 6 (Continued)

Patient number	1	2	3	4	5	6	7	8	9	10	11
Decimal age at review	0.67 years	11.32 years	16.24 years	10.95 year	12.58 years	2.77 years	2.58 years	4.09 years	15.85 years	11.75 years	9.99 years
Mat illness	—	—	—	—	+	—	—	—	—	+	—
Gestation (weeks)	41	28	40	40	32	41	35	39	41	39	40
Admitted SCBU	—	n/a	—	—	+	—	+ 14 days	—	+ 1 day	—	+ 7 days
Feeding problems	+	—	—	+	+	—	+	—	—	—	+ NGT
Height (percentile)	8.33	n/a	1	4	11	3	42	n/a	1	1	2
Age height measured	11 months	n/a	4 years	9 years	12 years	33 months	2 months	n/a	4 years	8 years	6 years
Birth weight (percentile)	3.2	99	3	1	92	90	33	10	5	10	62
Weight (percentile)	8.39	n/a	35	n/a	99	98	33.5	n/a	1	14	66
Age weight measured	11 months	n/a	4 years	n/a	12 years	33 months	2 months	n/a	4 years	8 years	6 years
OFC (percentile)	43	1	58	23	36	64	n/a	9	1	51	56
Age OFC measured	11 months	8 years	4 years	9 years	12 years	birth	n/a	17 months	4 years	birth	6 years
Social smile	n/a	n/a	n/a	n/a	n/a	n/a	n/a	6 weeks	Unknown	9 weeks	5 months
Sat independently	n/a	6 months	10 months	18 months	n/a	9 months	2–2.5 years	12 months	6 months	12 months	2–2.5 years
Walked independently	n/a	2–2.5 years	20 months	2.5–3 years	2.5–3 years	2–2.5 years	Not yet achieved	n/a	2–2.5 years	Not yet achieved	12 months
First words	n/a	13 months	18 months	2.5–3 years	5 years and over	2.5–3 years (2-to 3-word sentences aged 6)	2–2.5 years	n/a	3–4 years	Single word at 2 years, regression to no speech	Unknown
Prior pregnancy loss in this relationship	0	0	0	3+	0	0	0	0	0	0	0
Consanguinity	No	No	No	No	No	No	No	No	No	No	No
Is patient only affected member of family	Yes	Yes	Yes	Yes	Yes	Yes	Yes	Yes	No	No	Yes
Patient phenotype reminiscent of known syndrome	+SMA, Prader–Willi, myotonic dystrophy	—	—	Angelman syndrome	—	—	+Congenital myasthenic syndrome	—	+ Cornelia de Lange	—	+ Angelman's, Fragile X, Rett X inactivation, Smith Magenis
Cranial MRI	Normal	Abnormal	n/a	Normal	Normal	Abnormal	Normal	Abnormal	Normal	Abnormal	Normal

TABLE 7 Phenotypic data patients 12–21

Patient number	12	13	14	15	16	17	18	19	20	21
Decipher ID	DDD-272038	DDD-270543	n/a	n/a	n/a	n/a	DDD-268082	n/a	n/a	n/a
Genotype	c.1801C>T	c.847_857del	c.837_839del	c.2167+35_+415del	c.1089 G>A	c.1641delA	c.1681del	c.454_466del	c.706_707del	c.712_715del
Protein change	p.Arg601Ter	p.Phe283SerfsTer5	p.Glu279del	5.6kb deletion of final 3 exons (12-14)	p.Trp363*	Asp548Ilefs*5	Gln561SerfsTer45	Ala152ThrfsTer	p.Glu236Thrfs*6	p.Lys238AlafsTer100
Het/homozygous	Het	Het	Het	Het	Het	Het	Het	Het	Het	Het
Gender	M	F	M	M	F	F	M	F	F	F
Developmental delay	Present	Severe, stereotypy	Present	Global, moderate motor delay	Severe	Severe	Severe	Severe	Moderate to severe	Unknown
Speech impairment	Speech therapy	2 words- mum & dad	Delayed	Severe, single words at 5 years	Absent speech	No speech, only one word	Regression can only say "mummy"	Single words only	Delayed	Delayed
Degree of ID	Cognitive impairment	n/a	Moderate, total IQ 52	Moderate (special unit in mainstream school, 1:1 help)	Severe	Only word: "Hi-ya"	Only word "mummy"	Some basic understanding	n/a	n/a
Behavior	Autistic	Hand stereotypies; bruxism	No	Some aggressive outbursts, no sense of danger	Bruxism	Generally, content but capable of tantrums	n/a	Very stubborn, autistic features	None diagnosed but it can be difficult.	Autism spectrum disorder diagnosed
Stature	n/a	Short	Slender build: -2 SD	Normal	n/a	Small	n/a	0.4th centile	n/a	n/a
Craniofacial dysmorphism	Abnormal facial shape, prominent, heavy wide arched eyebrows, triangular face, flat cheekbones	Strabismus, drooling, prominent nasal bridge, wide nasal bridge, bruxism	Dolichocephaly, prominent forehead, down slant, slightly low hanging columella, thin upper lip	Left-sided plagiocephaly, torticollis, low-set ears, prominent forehead, epicanthic folds (L>R), prominent nasal tip, sparse hair, mild hypermetropia	Dysplastic earlobes, short palpebral fissures, broad nasal bridge, hypoplastic alae nasi, tented upper lip, prominent jaw, microcephaly	Mild synophrys, short nose	Coarse facial features, epicanthus, high arched eyebrow, long palpebral fissure, trigonoccephaly, widely spaced teeth	Broad forehead, small chin, bilateral glue ear, exotropia	Up slanting palpebral fissures, long eyelashes, thin upper lip	Frontal bossing, prominent metopic suture, flattened nasal bridge, short nose,
Chest/upper limbs/hands	n/a	Short 4 th /5 th metacarpal, tapered finger,	Long fingers	n/a	Small hands and feet, tapering fingers,	Short fingers	Prominent fingertip pads, broad thumb	None	Broad thumbs	Bilateral postaxial polydactyly

TABLE 7 (Continued)

Cardiac/other organ abnormality	n/a	rhizomatic shortening	n/a	bilateral single palmar creases; short fifth fingers	n/a	Kyphosis and bilateral valgus deformity	Lordosis, constipation	Scoliosis, ASD	Orchidopexy for undescended testis	
Lower limbs	n/a	Broad based gait	Long toes	Unsteady gait, frequent falls	n/a	Short toes	None	Pes plaus, cold feet	None	
Seizures	+ (2 in lifetime)	Episodic hyperventilation interspersed with apnoea associated with cyanosis	+ Focal	+(none since 4 years old)	+Febrile	+Controlled	+Febrile seizures present, myoclonic seizures, atypical absences, later emergence of tonic seizures, and gelastic seizures.	+ Tonic-clonic, atypical absences, later emergence of tonic seizures, and gelastic seizures.	+ on Keppra	
Musculature	n/a	n/a	n/a	Low muscle tone, especially core tone	n/a	Reduced tone	Reduced tone	n/a	Hypotonia, joint laxity	
Patient number	12	13	14	15	16	17	18	19	20	21
Decimal age at review	16.68 years	17.63 years	13 years	5.7 years	n/a	n/a	13.9 years	8.5 years	23 years	5 years
Mat illness	—	—	—	—	n/a	—	—	+	(pre-eclampsia causing emergency cesarean)	—
Gestation (weeks)	40	37	40	39	Post-term	39	36	28+5	40+9	40+2
Admitted SCBU	—	No	+ 1 day	—	n/a	+	—	+45 days	+ brief period	—
Feeding problems	—	No	—	—	n/a	+	+	+Necrotizing enterocolitis	—	—
Height (percentile)	1	3	13.6	30	n/a	119 cm (percentile n/a)	7	110 cm (percentile n/a)	141 cm (percentile n/a)	n/a
Age height measured	15 years	3 years	13.5	4 (+2 months)	n/a	11 years, 5 months	8 years	8 years	23 years	n/a
Birth weight (percentile)	22	56	9	91	75–91st	50	8	9	2–9	2

(Continues)

TABLE 7 (Continued)

Weight (percentile)	5	18 kg (percentile n/a)	32.7 kg (percentile n/a)	82	n/a	29 kg (percentile n/a)	95	30 kg (percentile n/a)	46	n/a
Age weight measured (years)	15 years	7.5 years	13.5 years	5 (+3 months)	n/a	11 years 5 months	8 years	8 years + 6 months	23 y	n/a
OFC (percentile)	n/a	10	57.2 cm (percentile n/a)	99	n/a	49.5 cm (percentile n/a)	26	2	51	3.6
Age OFC measured (years)	n/a	3 years	13.5 years	5 (+3 months)	n/a	11 years 5 months	8 years	Birth	23 years	Birth
Social smile	Unknown	Unknown	Unknown	unknown	n/a	n/a	8 weeks	Unknown	Unknown	Unknown
Sat Independently	Unknown	15 months	Unknown	12 months	n/a	3 years	14 months	Unknown	Unknown	16 months
Walked independently	Unknown	2.5–3 years	2 years	2 years	Non-mobile	5–8 years	2–2.5 years	2 years	2 years	3 years
First words	Unknown	3 years	2 years	2.5 years	n/a	None	not yet achieved	3.5 years	2 years	14 months
Prior pregnancy loss in this relationship	0	0	0	0	n/a	2	0	unknown	unknown	3
Is there consanguinity	No	No	No	No	n/a	No	No	No	No	No
Is patient only affected member of family	Yes	Yes	Yes	Yes	Yes	Yes	Yes	Yes	Yes	Yes
Patient phenotype reminiscent of known syndrome	+, Cornelia-de Lange	+, Rett Pitt Hopkin	–	+, Mild Angelman	+, Rett	–	–	+ Rett	+, Cornelia de Lange	–
Cranial MRI	n/a	n/a	Normal	Normal	Normal	Normal	Abnormal	Abnormal	Normal	Normal

this gene, we are unable to back this by clinical evidence. The majority of identified missense and in-frame deletions published so far are outside of the p.521-p.640 region upstream of the RGG domain, that is, p. (Glu140Lys) (Yates et al., 2017); p.(Arg324Gly), p.(Thr582_Gln589del), p. (Ser378Pro) (Bramswig et al., 2017); and the p.(Glu279del) region in our study. Therefore, without functional studies, we cannot propose the presence of a mutation hotspot within the gene. On the other hand, the *HNRNPU* gene pLI score is 1 (pLI ≥ 0.9 are extremely LoF intolerant), suggesting haploinsufficiency as the main mechanism of pathogenicity in this gene. This is backed with genotypic data presented in our study and previously published work.

It is worth noting that although rare, there are handful numbers of apparently healthy individuals reported in gnomAD with truncating variants predicted to result in NMD and haploinsufficiency: gnomAD v2.1.1 accessed 23rd March 2020; Genome build GRCh37/hg19; Ensembl gene ID ENSG00000153187.12; Canonical transcript ID ENST00000283179.9 (<https://gnomad.broadinstitute.org>). This is not unusual as not all individuals in gnomAD are completely disease-free and detailed phenotypic information is not always available. Therefore, our work is vital in avoiding misclassification of these variants based on their presence at low frequency in control population data. One of the main ACMG criteria used to achieve pathogenic classification was PS2 (de novo), highlighting the importance of testing parents if appropriate in newly diagnosed cases to check if the variant has risen *de novo* in the proband.

5 | CONCLUSIONS

In summary, we present here the largest cohort of *HNRNPU*-related syndrome to date comprising ID, behavioral disorders, epilepsy, and craniofacial dysmorphism. This follows on from the previous paper from our group (Yates et al., 2017). The data presented here broaden the phenotypic spectrum establishing similar patterns of seizure profiling and development to previously published literature.

ACKNOWLEDGMENTS

The DDD study presents independent research commissioned by the Health Innovation Challenge Fund (Grant No. HICF-1009-003). This study makes use of DECIPHER (<http://decipher.sanger.ac.uk>), which is funded by the Wellcome. See *Nature* PMID: 25533962 or www.ddduk.org/access.html for full acknowledgement. We would also like to thank all the families for consenting to this publication.

CONFLICT OF INTEREST

The authors declare no conflict of interest.

AUTHOR CONTRIBUTIONS

MB designed the study, supervised data collection, and takes the overall responsibility for the final manuscript; AD contributed to data collection and wrote manuscript; all co-authors contributed to data collection and approval of final manuscript.

DATA AVAILABILITY STATEMENT

The data that support the findings of this study are available from the Deciphering Developmental Disorders Study. Restrictions apply to the availability of these data, which were used under license for this study. Data are available from Meena Balasubramanian/ <https://decipher.sanger.ac.uk/ddd#overview> with the permission of the Deciphering Developmental Disorders Study.

ORCID

Anna Durkin  <https://orcid.org/0000-0002-4846-8900>

Alice Gardham  <https://orcid.org/0000-0002-6556-366X>

Meena Balasubramanian  <https://orcid.org/0000-0003-1488-3695>

REFERENCES

- Abou Tayoun, A. N., Pesaran, T., DiStefano, M. T., Oza, A., Rehm, H. L., Biesecker, L. G., & Harrison, S. M. (2018). ClinGen Sequence Variant Interpretation Working Group (ClinGen SVI). Recommendations for interpreting the loss of function PVS1 ACMG/AMP variant criterion. *Human Mutation*, 39(11), 1517–1524.
- Bi, H. S., Yang, X. Y., Yuan, J. H., Yang, F., Xu, D., Guo, Y. J., ... Sun, S. H. (2013). H19 inhibits RNA polymerase II-mediated transcription by disrupting the hnRNP U-actin complex. *Biochimica et Biophysica Acta*, 1830(10), 4899–4906.
- Bramswig, N. C., Lüdecke, H. J., Hamdan, F. F., Altmüller, J., Beleggia, F., Elcioglu, N. H., ... Kuechler, A. (2017). Heterozygous *HNRNPU* variants cause early onset epilepsy and severe intellectual disability. *Human Genetics*, 136(7), 821–834.
- Caliebe, A., Kroes, H. Y., van der Smagt, J. J., Martin-Subero, J. I., Tönnies, H., van't Slot, R., ... Stefanova, I. (2010). Four patients with speech delay, seizures and variable corpus callosum thickness sharing a 0.440 Mb deletion in region 1q44 containing the *HNRPU* gene. *European Journal of Medical Genetics*, 53(4), 179–185.
- Depienne, C., Nava, C., Keren, B., Heide, S., Rastetter, A., Passemard, S., ... Stoler, J. M. (2017). Genetic and phenotypic dissection of 1q43q44 microdeletion syndrome and neurodevelopmental phenotypes associated with mutations in *ZBTB18* and *HNRNPU*. *Human Genetics*, 136(4), 463–479.
- Havrilla, J. M., Pedersen, B. S., Layer, R. M., & Quinlan, A. R. (2019). A map of constrained coding regions in the human genome. *Nature Genetics*, 51(1), 88–95.
- Hasegawa, Y., Brockdorff, N., Kawano, S., Tsutui, K., Tsutui, K., & Nakagawa, S. (2010). The matrix protein hnRNP U is required for chromosomal localization of Xist RNA. *Developmental Cell*, 19(3), 469–476.
- Leduc, M. S., Chao, H. T., Qu, C., Walkiewicz, M., Xiao, R., Magoulas, P., ... Schaaf, C. P. (2017). Clinical and molecular characterization of de novo loss of function variants in *HNRNPU*. *American Journal of Medical Genetics Part A*, 173(10), 2680–2689.
- Need, A. C., Shashi, V., Hitomi, Y., Schoch, K., Shianna, K. V., McDonald, M. T., ... Goldstein, D. B. (2012). Clinical application of exome sequencing in undiagnosed genetic conditions. *Journal of Medical Genetics*, 49(6), 353–361.
- Nozawa, R. S., Boteva, L., Soares, D. C., Naughton, C., Dun, A. R., Buckle, A., ... Hill, B. (2017). SAF-A regulates interphase chromosome structure through oligomerization with chromatin-associated RNAs. *Cell*, 169(7), 1214–1227.
- Richards, S., Aziz, N., Bale, S., Bick, D., Das, S., Gastier-Foster, J., ... Voelkerding, K. (2015). Standards and guidelines for the interpretation of sequence variants: A joint consensus recommendation of the American College of Medical Genetics and Genomics and the Association for Molecular Pathology. *Genetics in Medicine*, 17(5), 405–423.
- Thierry, G., Bénétteau, C., Pichon, O., Flori, E., Isidor, B., Popelard, F., ... Cailley, D. (2012). Molecular characterization of 1q44 microdeletion in 11 patients reveals three candidate genes for intellectual disability and seizures. *American Journal of Medical Genetics Part A*, 158(7), 1633–1640.

Yates, T. M., Vasudevan, P. C., Chandler, K. E., Donnelly, D. E., Stark, Z., Sadedin, S., ... Balasubramanian, M. (2017). De novo mutations in HNRNPU result in a neurodevelopmental syndrome. *American Journal of Medical Genetics Part A*, 173(11), 3003–3012.

SUPPORTING INFORMATION

Additional supporting information may be found online in the Supporting Information section at the end of this article.

How to cite this article: Durkin A, Albaba S, Fry AE, et al. Clinical findings of 21 previously unreported probands with HNRNPU-related syndrome and comprehensive literature review. *Am J Med Genet Part A*. 2020;182A:1637–1654. <https://doi.org/10.1002/ajmg.a.61599>